

CDES Presentations

Paul M. Karpecki, OD, FAAO

Director, Cornea & External Disease, Kentucky Eye Institute and
Carmel IN Center for Sight

Associate Professor, UPike Kentucky College of Optometry

Paul M. Karpecki, OD, FAAO
Financial Disclosures:

AI Optics
Aerie Pharmaceuticals
Akorn
Alcon Labs
Aldeyra
Allergan/Abbvie
Allysta pharmaceuticals
Amaros
Avellino Labs
Azura Pharmaceuticals
Bausch + Lomb
BioTissue
BlephEx
Bruder Healthcare
Bruno Vision Care
Cambium Pharma
Dompe
Eyedaptic
Eyedetec
Eyegate
Eyenvia
Eyevance
Gobiquity
Healthe

Hue.AI
iCare USA
Imprimis
Ivantis
Iveena
Jobson/Web MD
Johnson & Johnson Vision
Kala pharmaceuticals
KEPLR Vision
Konan Medical
Lacrisciences
LenTechs
Lombart/Marco
Maculogix
Mallinckrodt
Mitotech
Neurolens
Novaliq
Novartis
Oasis Medial
Oculus
OcuMedic
Ocuphire

Omega Ophthalmics
OcuSoft
Orasis
Oyster Point
RegenerEyes
Reichert
Rendia
RxSight
RVL
Science Based Health
Sentiss Pharma
Sight Sciences
Silk Technologies
Sun Pharmaceuticals
Surface Biopharma
Tarsus Medical
TearClear
TearLab
Visant Medical
Visionix
Vital Tears

*Introduction to Key
Concepts in DED
Understanding and
Diagnosis*

Lacrimal Functional Unit (LFU)

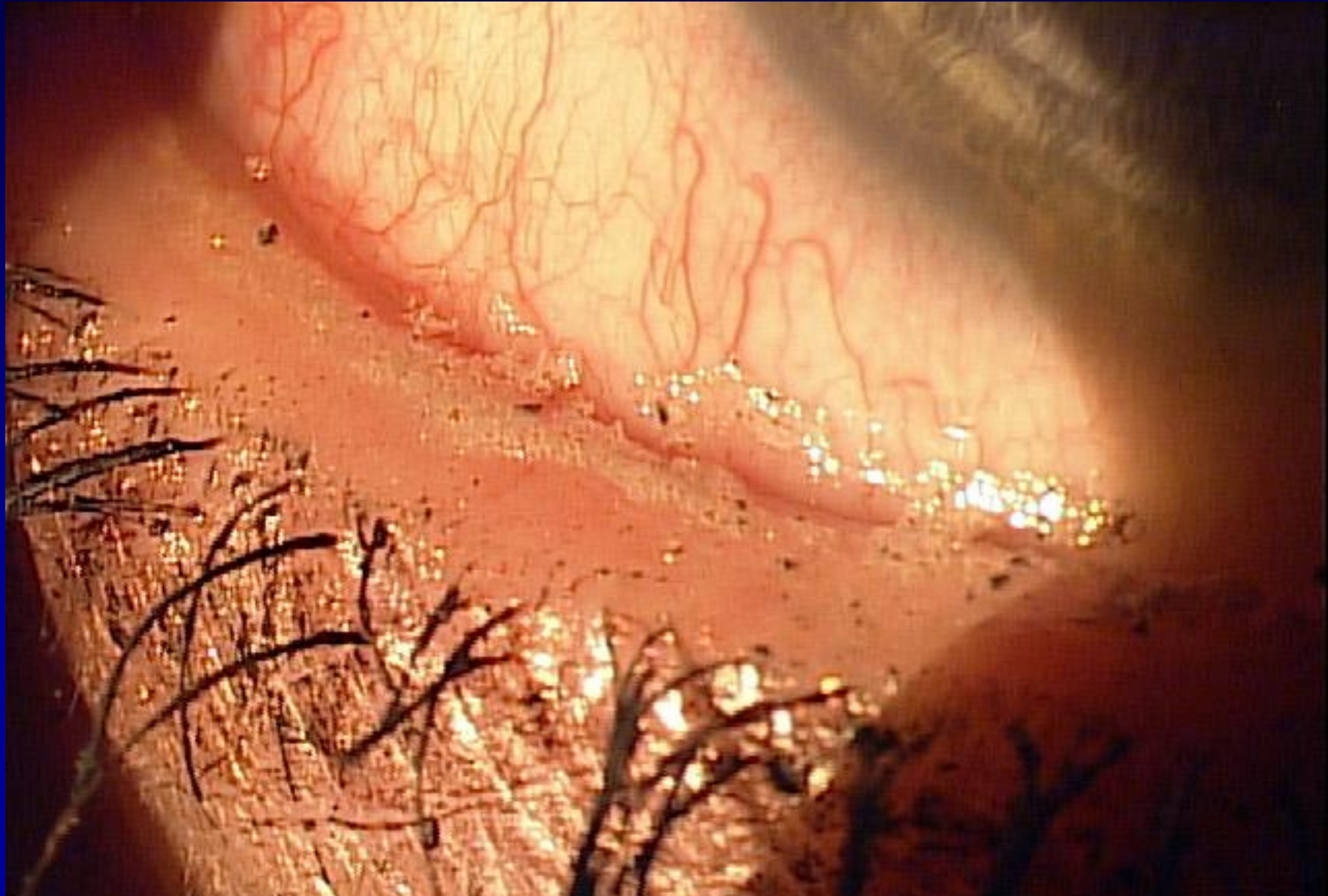
- Tear film
 - Lacrimal glands
 - Corneal and conjunctival epithelia
 - Meibomian glands
-
- Homeostasis controlled by nerve connections and systemic hormones

DED is an Immune-Mediated Disease

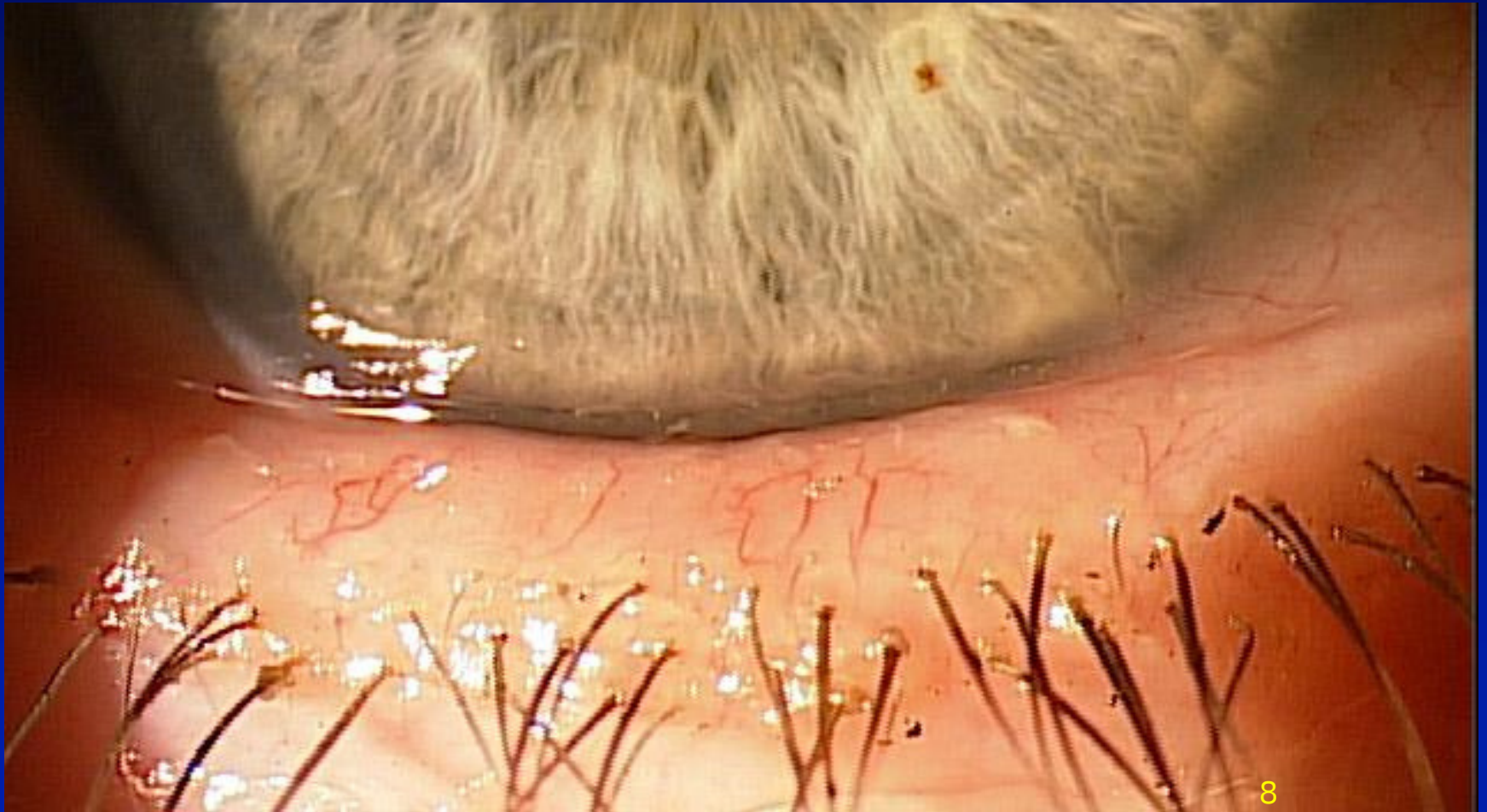
- Examples include asthma, RA etc
- Extreme example: anaphylaxis
- Treat before T-cell priming has been established

Begin with the Lid in Mind

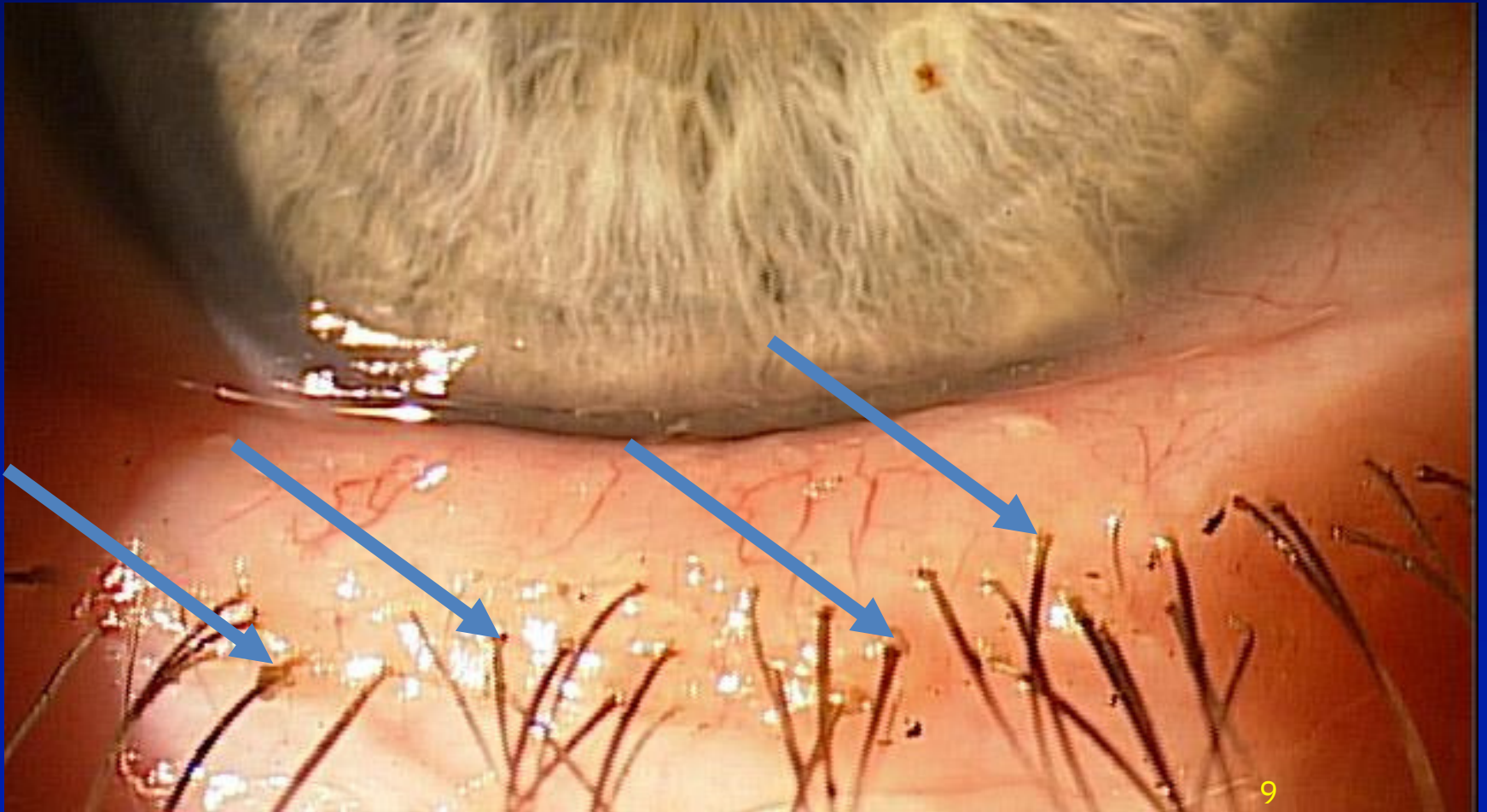
Frothy / Foamy Tears = MGD



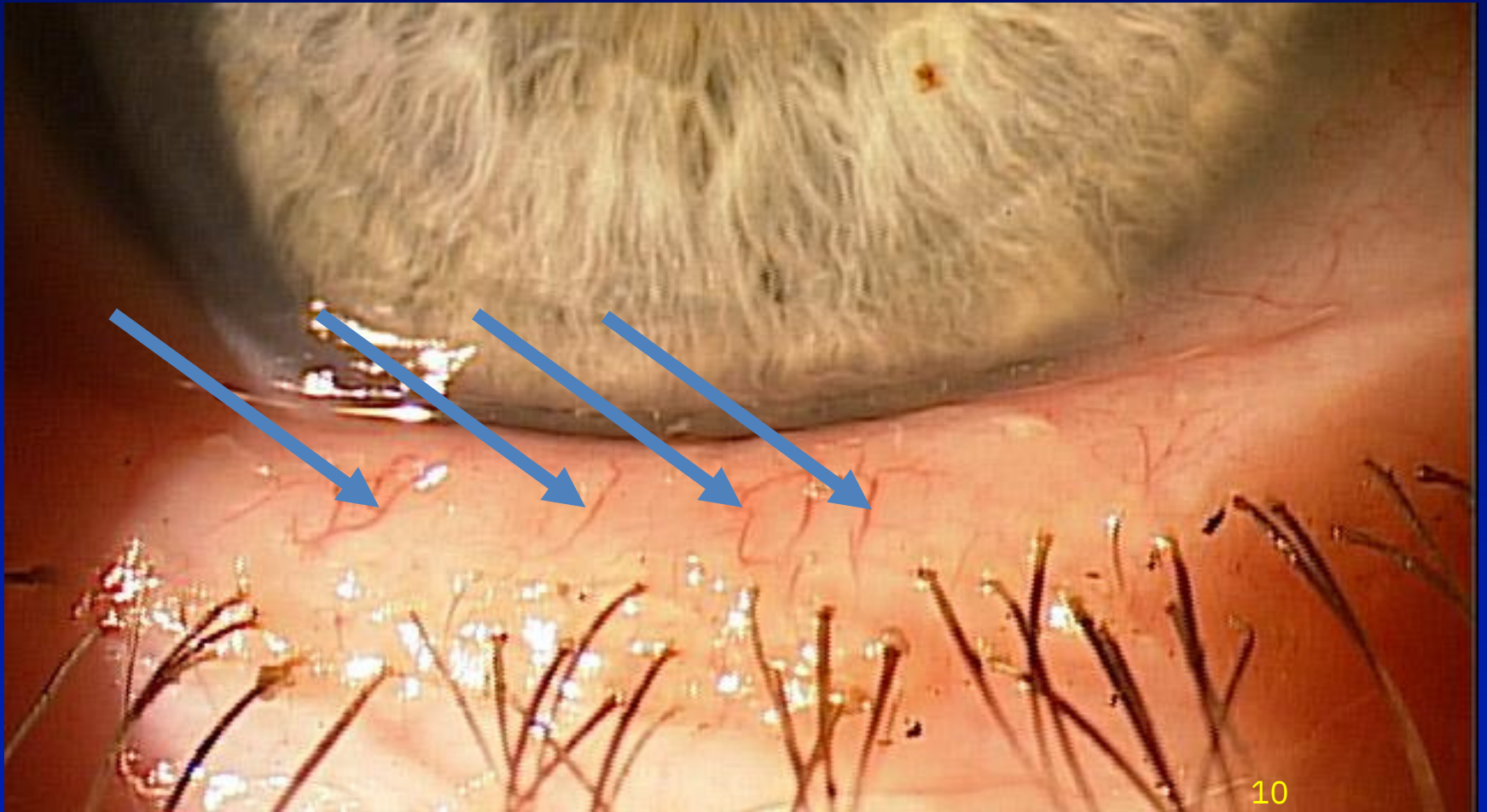
Significant Signs of Blepharitis



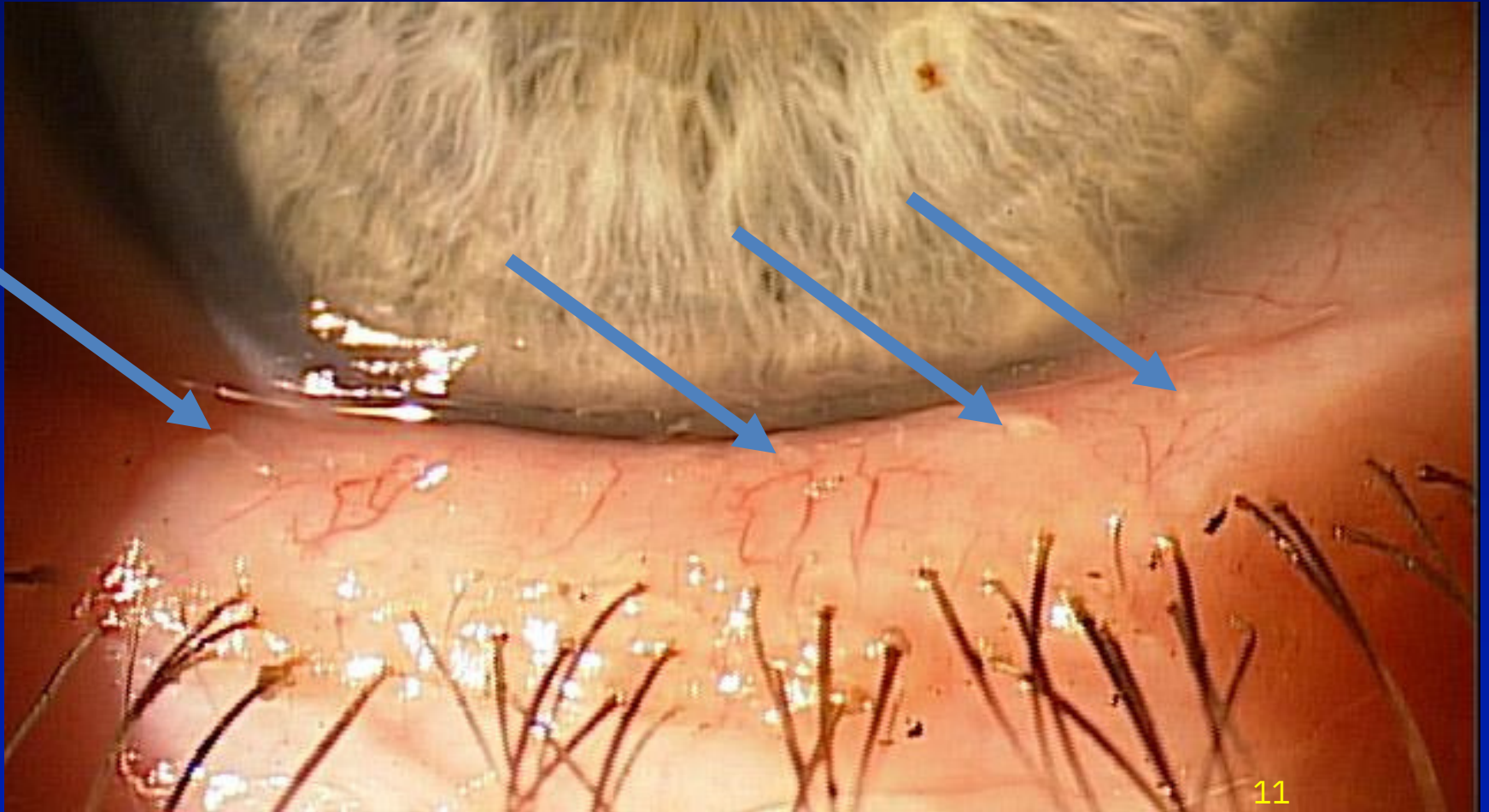
Collarettes/volcano sign



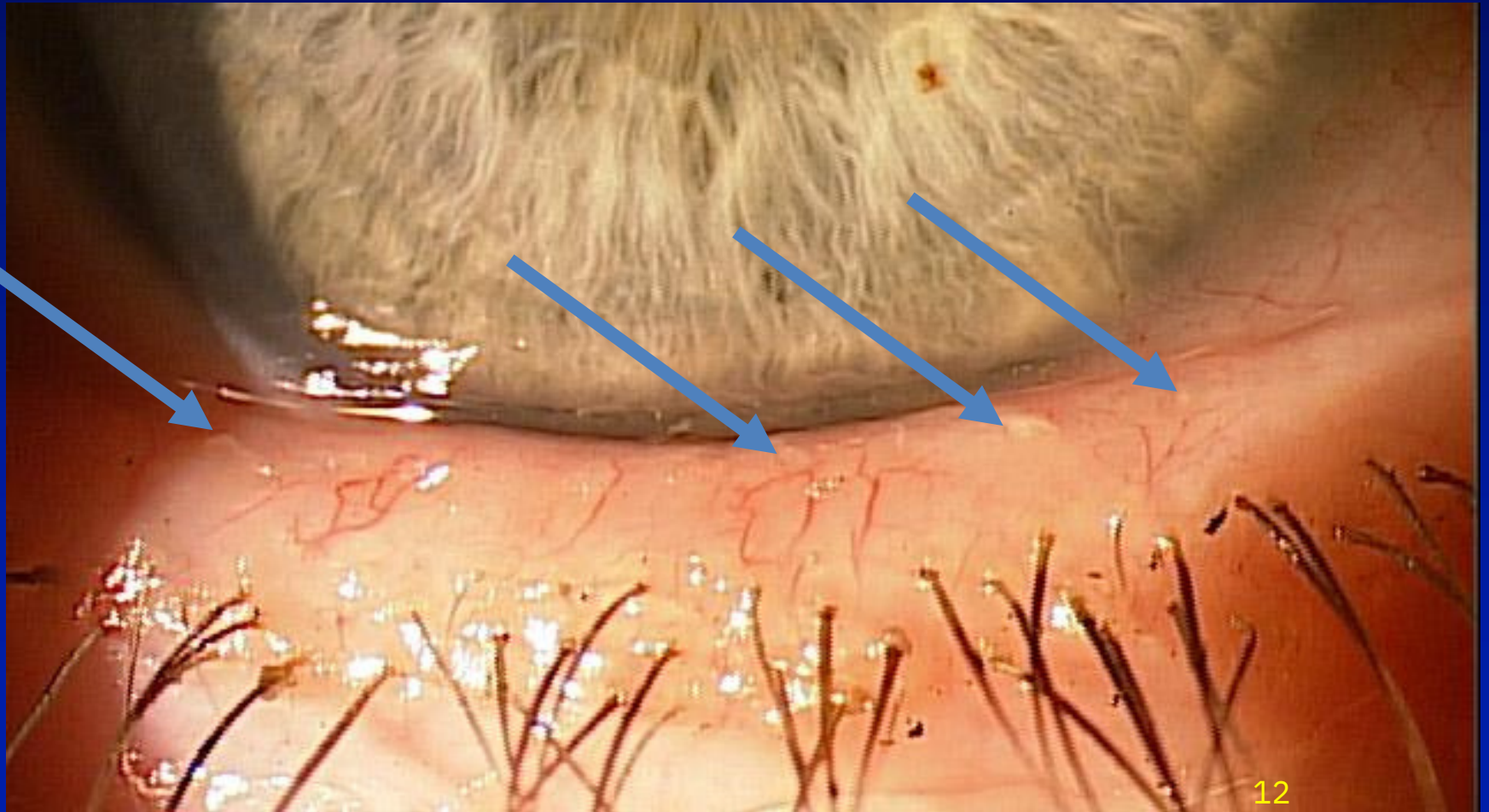
Telangiectatic vessels



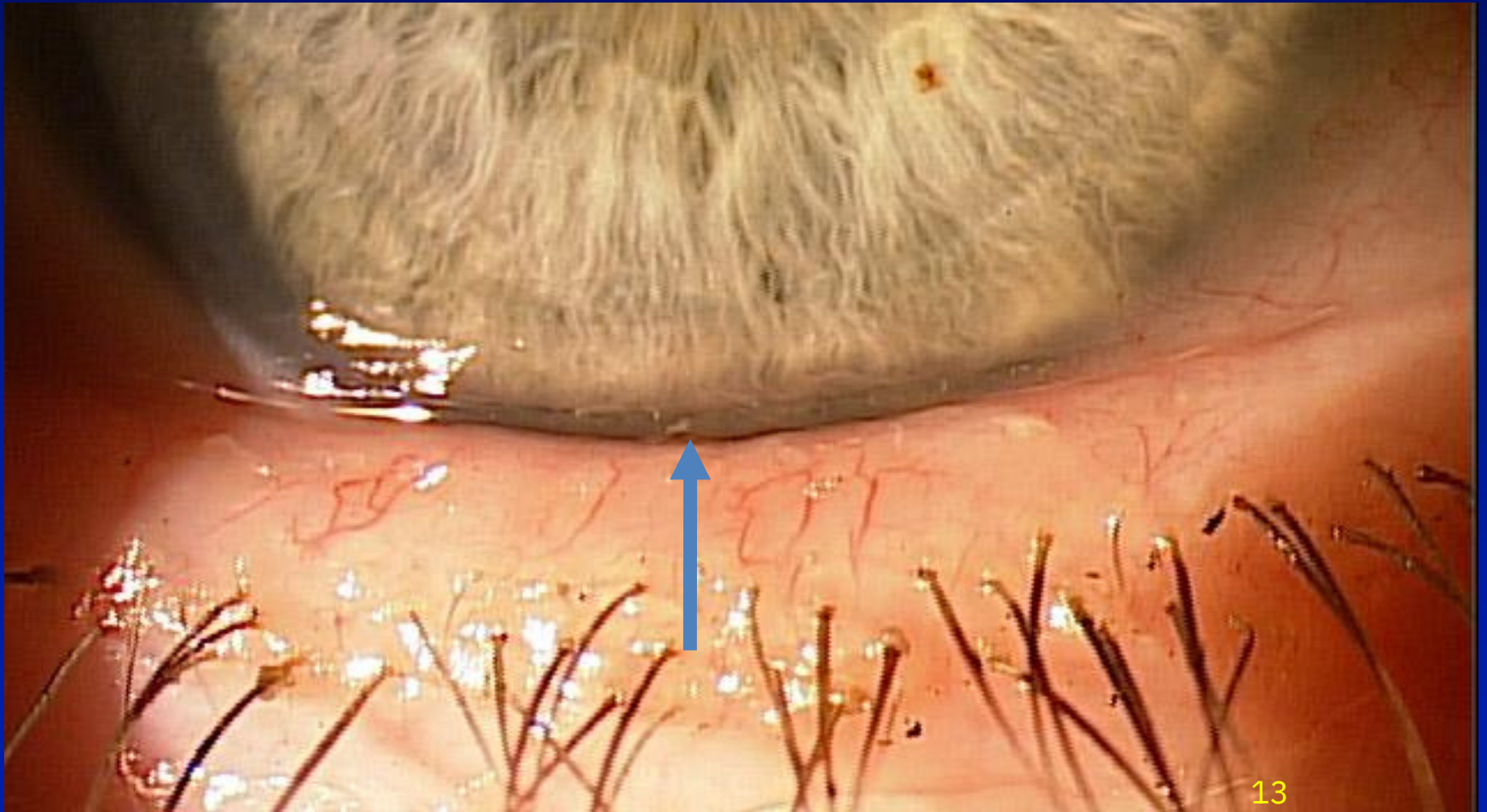
Capped MG's

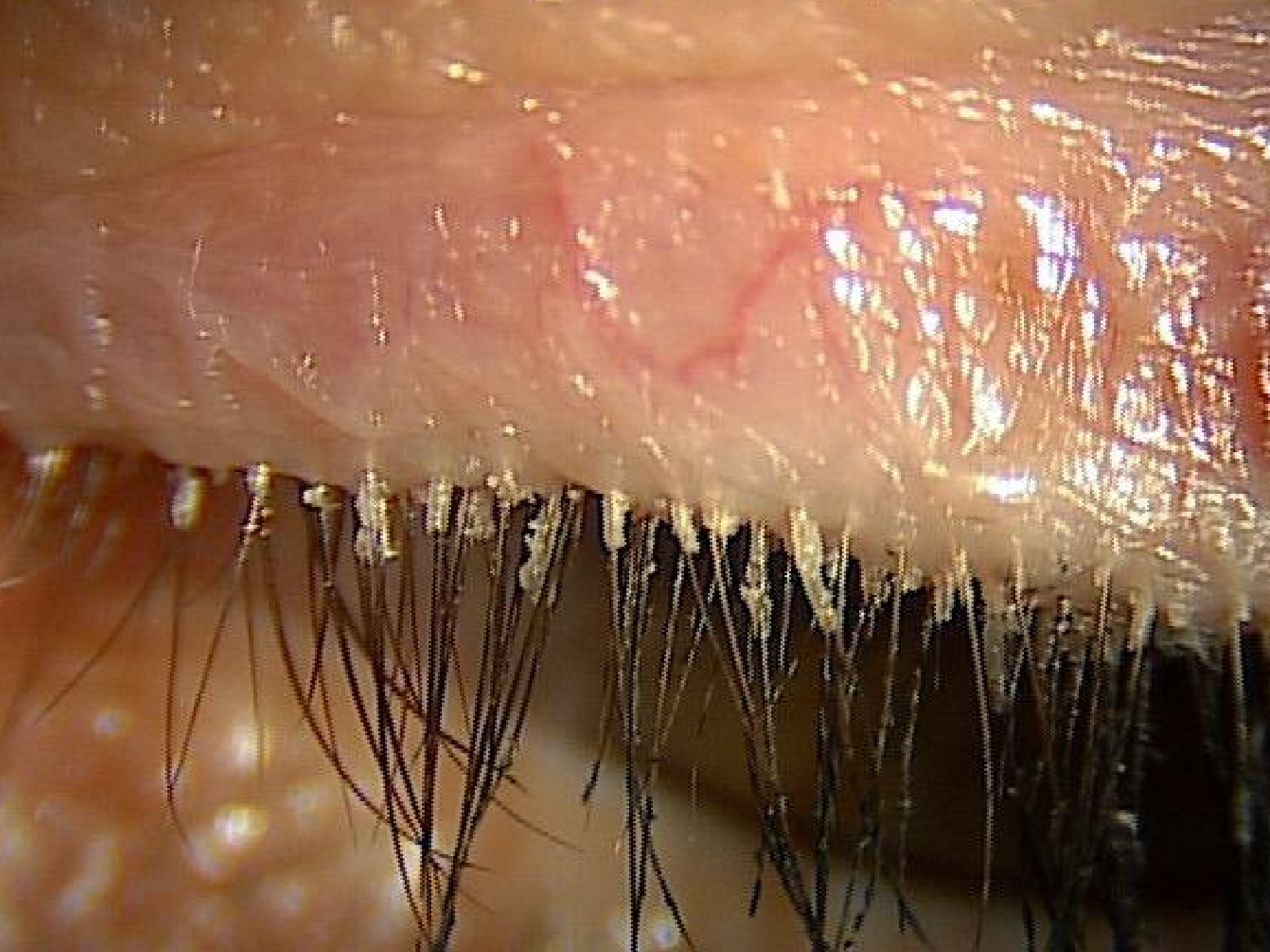

Posteriorly Positioned MGs



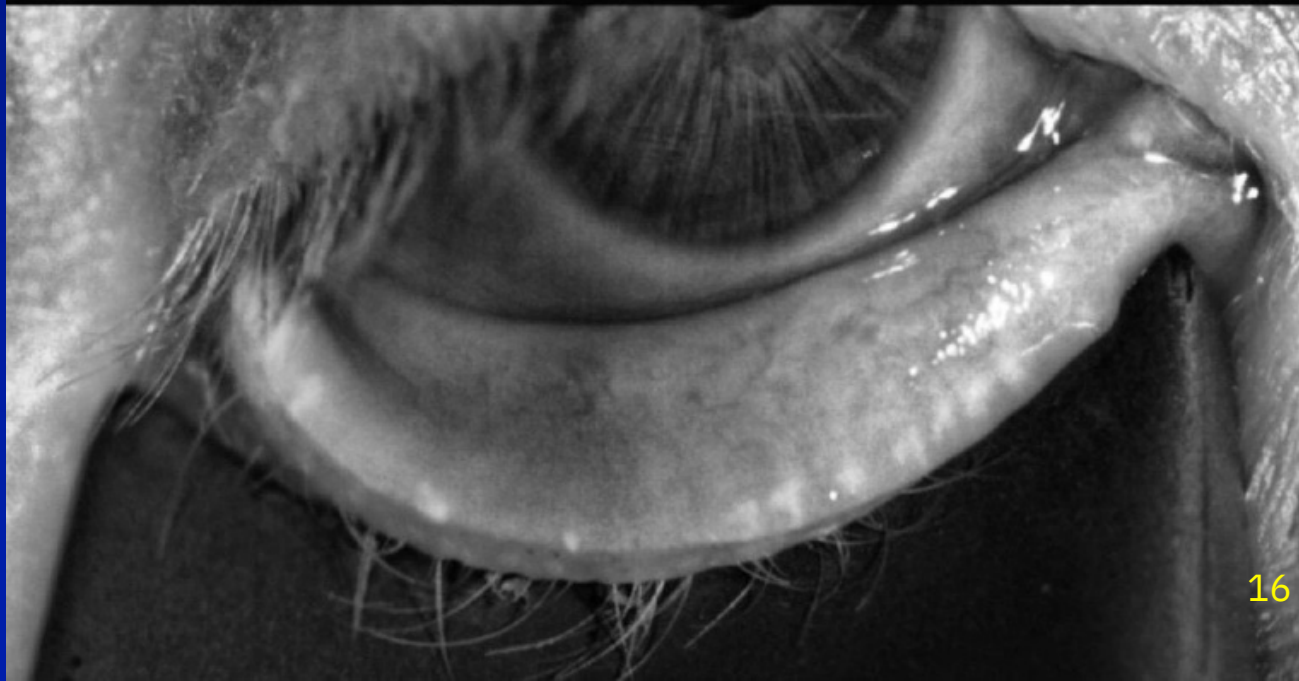
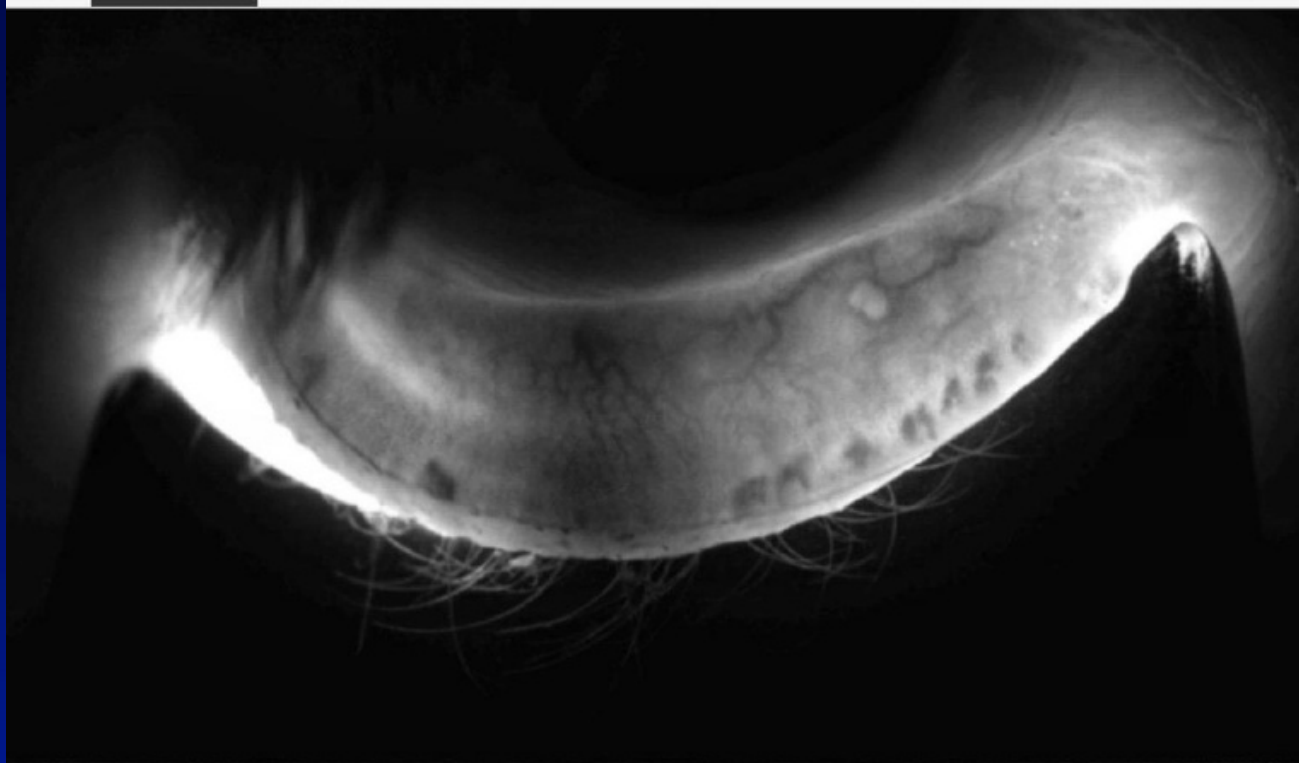
Tylosis



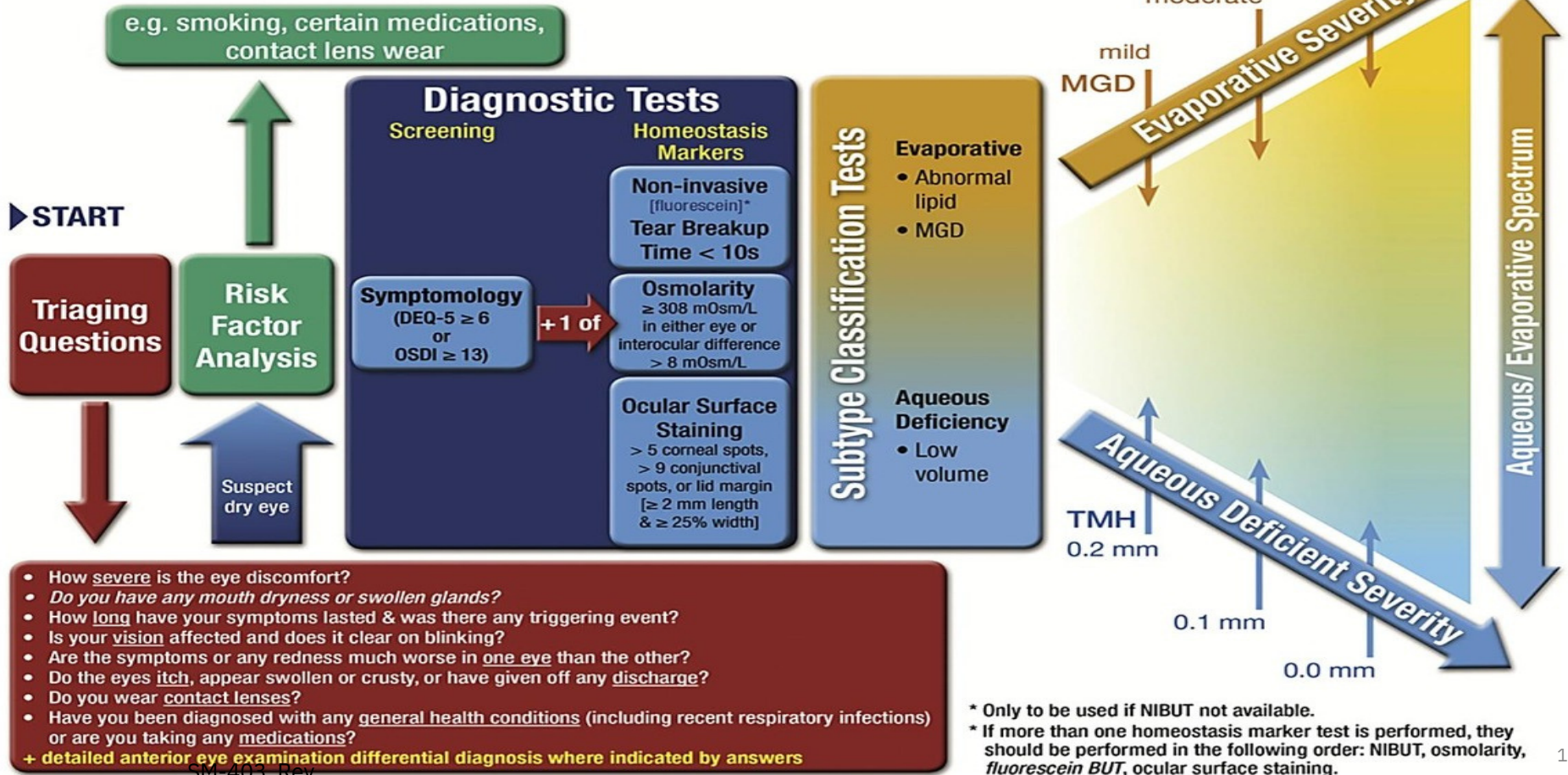


OS Lower Surface
9/19/2014 9:08:57 AM

 TearScience



Diagnostic methodology



SM-403, Rev

MGD lid margin drop-out, displacement, secretion ≥ 13 , expressibility 3
 + lipid pattern absent / globular / abnormal colored fringes

plugging, vascularity, secretion 8-12, expressibility 2
 + lipid pattern meshwork / wave (flow)

secretion 4-7, expressibility 1
 + lipid pattern amorphous / color fringes

e.g. smoking, certain medications,
 contact lens wear

▶ **START**

Triaging Questions

Risk Factor Analysis

Suspect dry eye

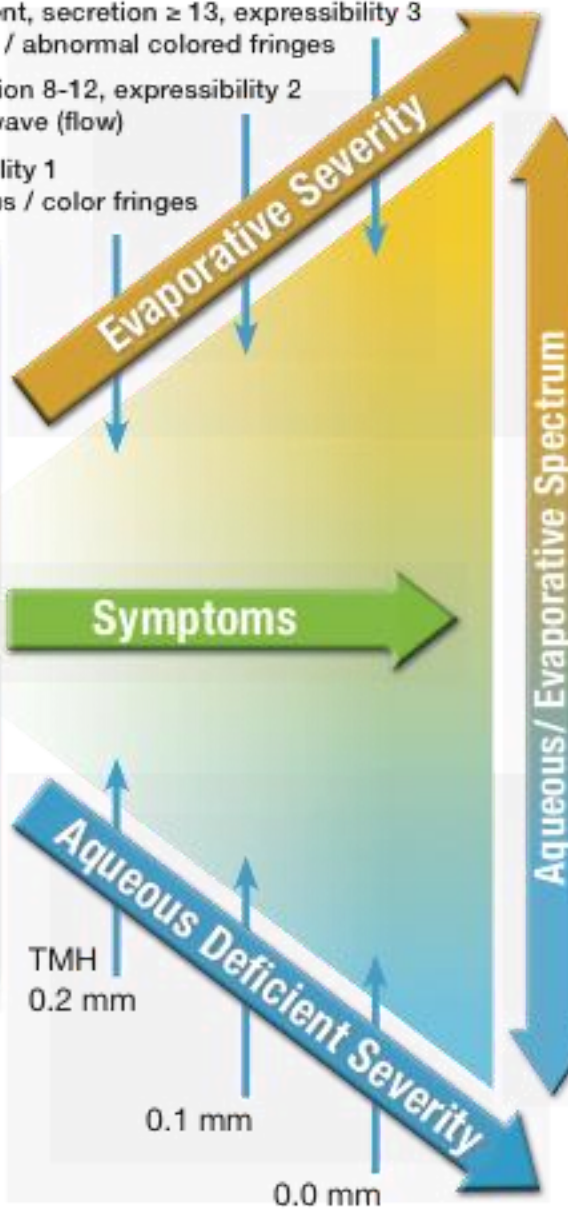
Diagnostic Tests

Screening	Homeostasis Markers
Symptomatology (DEQ-5 ≥ 6 or OSDI ≥ 13)	Non-invasive [fluorescein]* Tear Breakup Time < 10s
	Osmolarity ≥ 308 mOsm/L in either eye or interocular difference > 8 mOsm/L
	Ocular Surface Staining > 5 corneal spots, > 9 conjunctival spots, or lid margin [≥ 2 mm length & $\geq 25\%$ width]

+ 1 of

Subtype Classification Tests

- Evaporative**
 - Abnormal lipid
 - MGD
- Aqueous Deficiency**
 - Low volume



- How severe is the eye discomfort?
 - Do you have any mouth dryness or swollen glands?
 - How long have your symptoms lasted & was there any triggering event?
 - Is your vision affected and does it clear on blinking?
 - Are the symptoms or any redness much worse in one eye than the other?
 - Do the eyes itch, appear swollen or crusty, or have given off any discharge?
 - Do you wear contact lenses?
 - Have you been diagnosed with any general health conditions (including recent respiratory infections) or are you taking any medications?
- + detailed anterior eye examination differential diagnosis where indicated by answers

* only to be used if NIBUT not available and if so, after osmolarity



5 Triaging Questions from OD Summit



Do your eyes ever feel irritated, dry or burn?



Are your eyes red?



Do you experience blurred vision especially fluctuating vision?



Do you use or have the urge to use artificial tears?



How much time to you spend on digital devices per day?

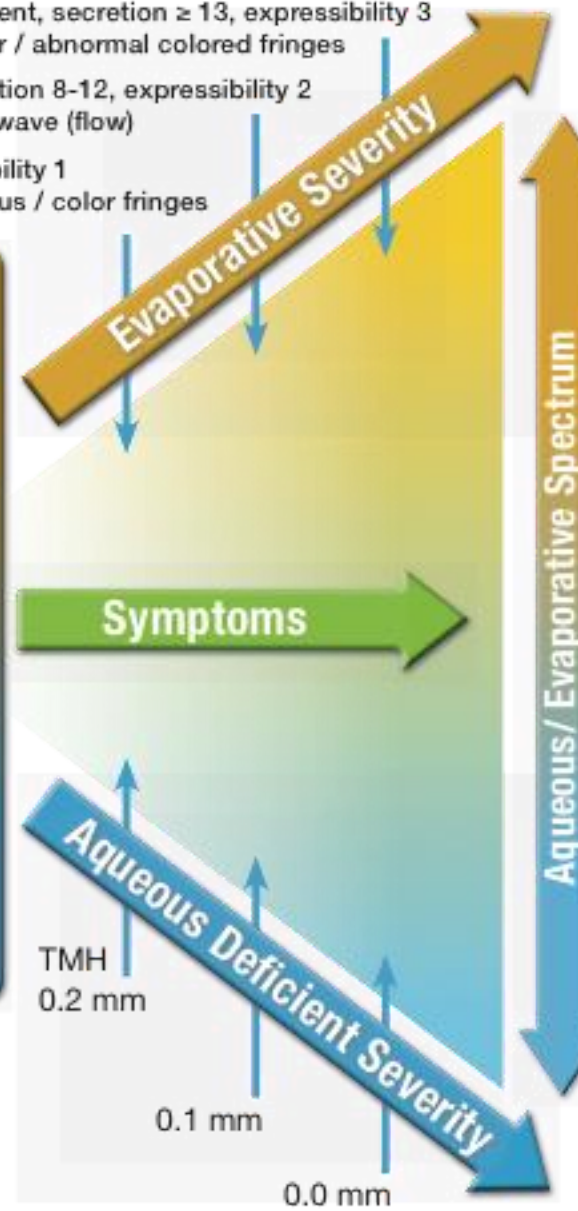
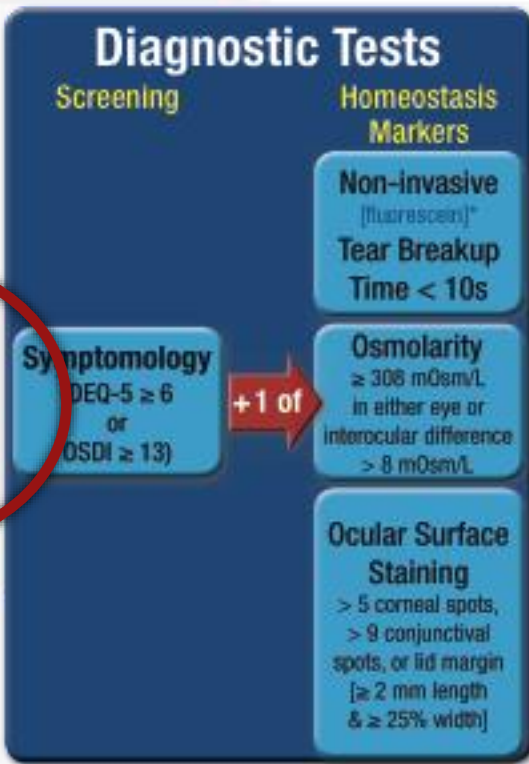
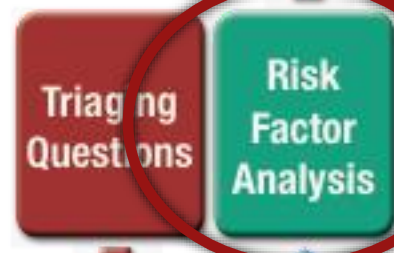MGD lid margin drop-out, displacement, secretion ≥ 13 , expressibility 3
 + lipid pattern absent / globular / abnormal colored fringes

plugging, vascularity, secretion 8-12, expressibility 2
 + lipid pattern meshwork / wave (flow)

secretion 4-7, expressibility 1
 + lipid pattern amorphous / color fringes

e.g. smoking, certain medications,
 contact lens wear

▶ **START**



- How severe is the eye discomfort?
 - Do you have any mouth dryness or swollen glands?
 - How long have your symptoms lasted & was there any triggering event?
 - Is your vision affected and does it clear on blinking?
 - Are the symptoms or any redness much worse in one eye than the other?
 - Do the eyes itch, appear swollen or crusty, or have given off any discharge?
 - Do you wear contact lenses?
 - Have you been diagnosed with any general health conditions (including recent respiratory infections) or are you taking any medications?
- + detailed anterior eye examination differential diagnosis where indicated by answers

* only to be used if NIBUT not available and if so, after osmolarity



Risk Factors for Dry Eye Disease



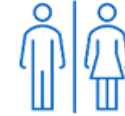Systemic
Medications



Topical
Medications



Age



Gender



Contact Lens
Wear



Ocular Surgery



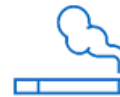Environment



Digital Devices



Systemic
Disease



Smoking



Certain Anterior
Segment
Diseases

MGD lid margin drop-out, displacement, secretion ≥ 13 , expressibility 3
 + lipid pattern absent / globular / abnormal colored fringes

plugging, vascularity, secretion 8-12, expressibility 2
 + lipid pattern meshwork / wave (flow)

secretion 4-7, expressibility 1
 + lipid pattern amorphous / color fringes

e.g. smoking, certain medications,
 contact lens wear

▶ **START**

Triaging Questions

Risk Factor Analysis

Symptomatology
 (DEQ-5 ≥ 6
 or
 OSDI ≥ 13)

+ 1 of

Non-invasive
 [fluorescein]*
Tear Breakup Time < 10s

Osmolarity
 ≥ 308 mOsm/L
 in either eye or
 interocular difference
 > 8 mOsm/L

Ocular Surface Staining
 > 5 corneal spots,
 > 9 conjunctival spots, or lid margin
 (≥ 2 mm length & $\geq 25\%$ width)

Diagnostic Tests

Screening

Homeostasis Markers

Subtype Classification Tests

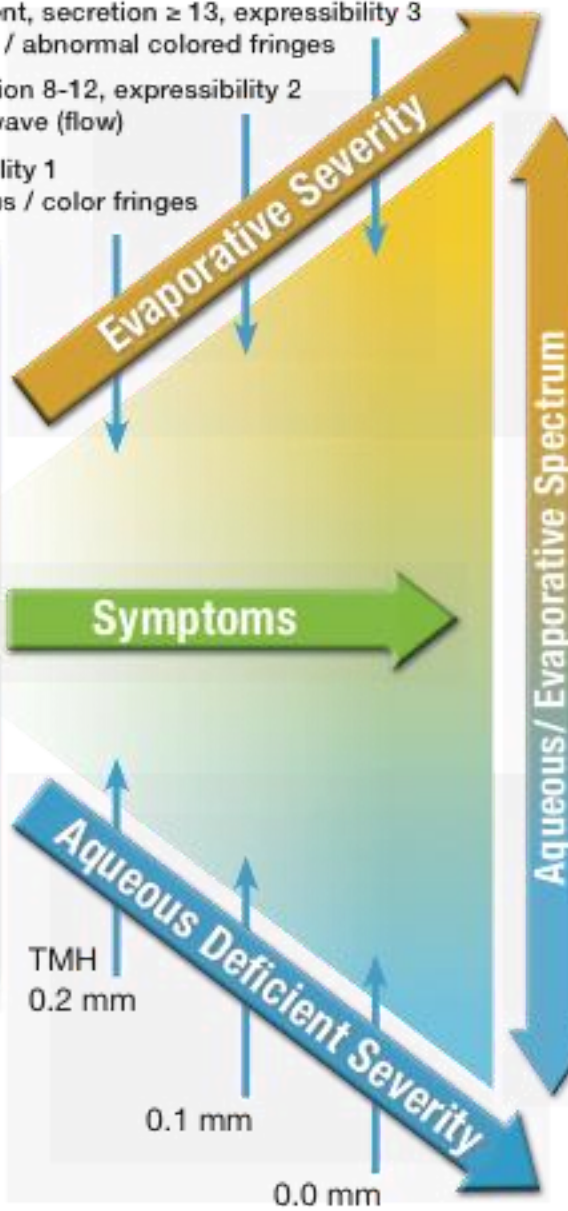
Evaporative

- Abnormal lipid
- MGD

Aqueous Deficiency

- Low volume

Symptoms



- How severe is the eye discomfort?
 - Do you have any mouth dryness or swollen glands?
 - How long have your symptoms lasted & was there any triggering event?
 - Is your vision affected and does it clear on blinking?
 - Are the symptoms or any redness much worse in one eye than the other?
 - Do the eyes itch, appear swollen or crusty, or have given off any discharge?
 - Do you wear contact lenses?
 - Have you been diagnosed with any general health conditions (including recent respiratory infections) or are you taking any medications?
- + detailed anterior eye examination differential diagnosis where indicated by answers

* only to be used if NIBUT not available and if so, after osmolarity



Questionnaires

DEQ-5

OSDI

SPEED

MGD lid margin drop-out, displacement, secretion ≥ 13 , expressibility 3
 + lipid pattern absent / globular / abnormal colored fringes

plugging, vascularity, secretion 8-12, expressibility 2
 + lipid pattern meshwork / wave (flow)

secretion 4-7, expressibility 1
 + lipid pattern amorphous / color fringes

e.g. smoking, certain medications,
 contact lens wear

▶ **START**

Triaging Questions

Risk Factor Analysis

Diagnostic Tests

Screening

Symptomatology (DEQ-5 ≥ 6 or OSDI ≥ 13)

+ of

Homeostatic Markers

Non-invasive [fluorescein]*
 Tear Breakup Time < 10s

Osmolarity ≥ 308 mOsm/L in either eye or interocular difference > 8 mOsm/L

Ocular Surface Staining > 5 corneal spots, > 9 conjunctival spots, or lid margin (≥ 2 mm length & $\geq 25\%$ width)

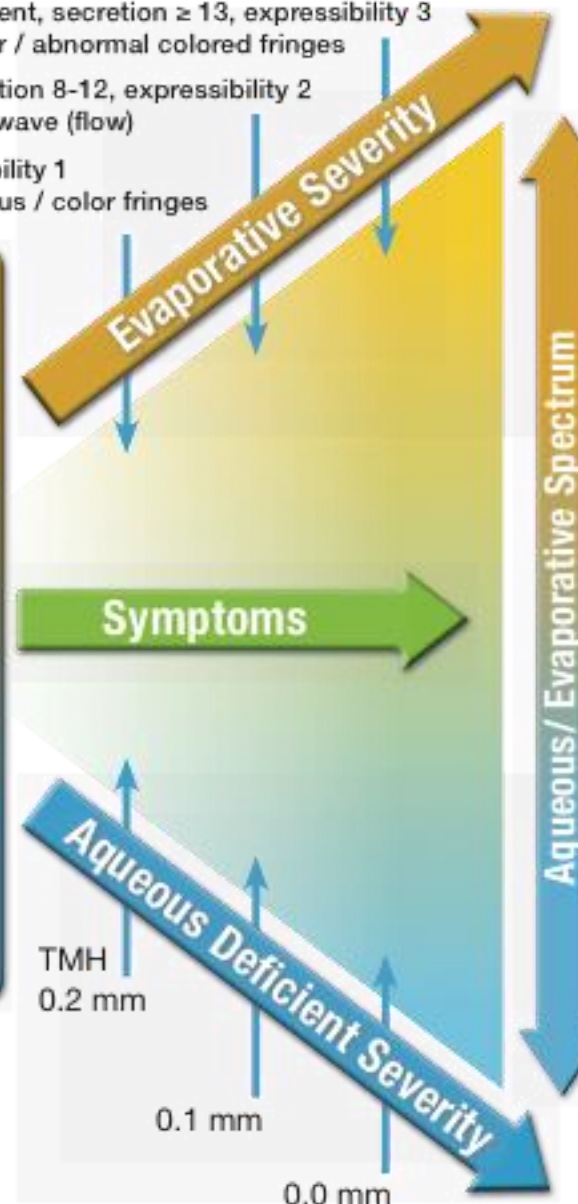
Subtype Classification Tests

Evaporative

- Abnormal lipid
- MGD

Aqueous Deficiency

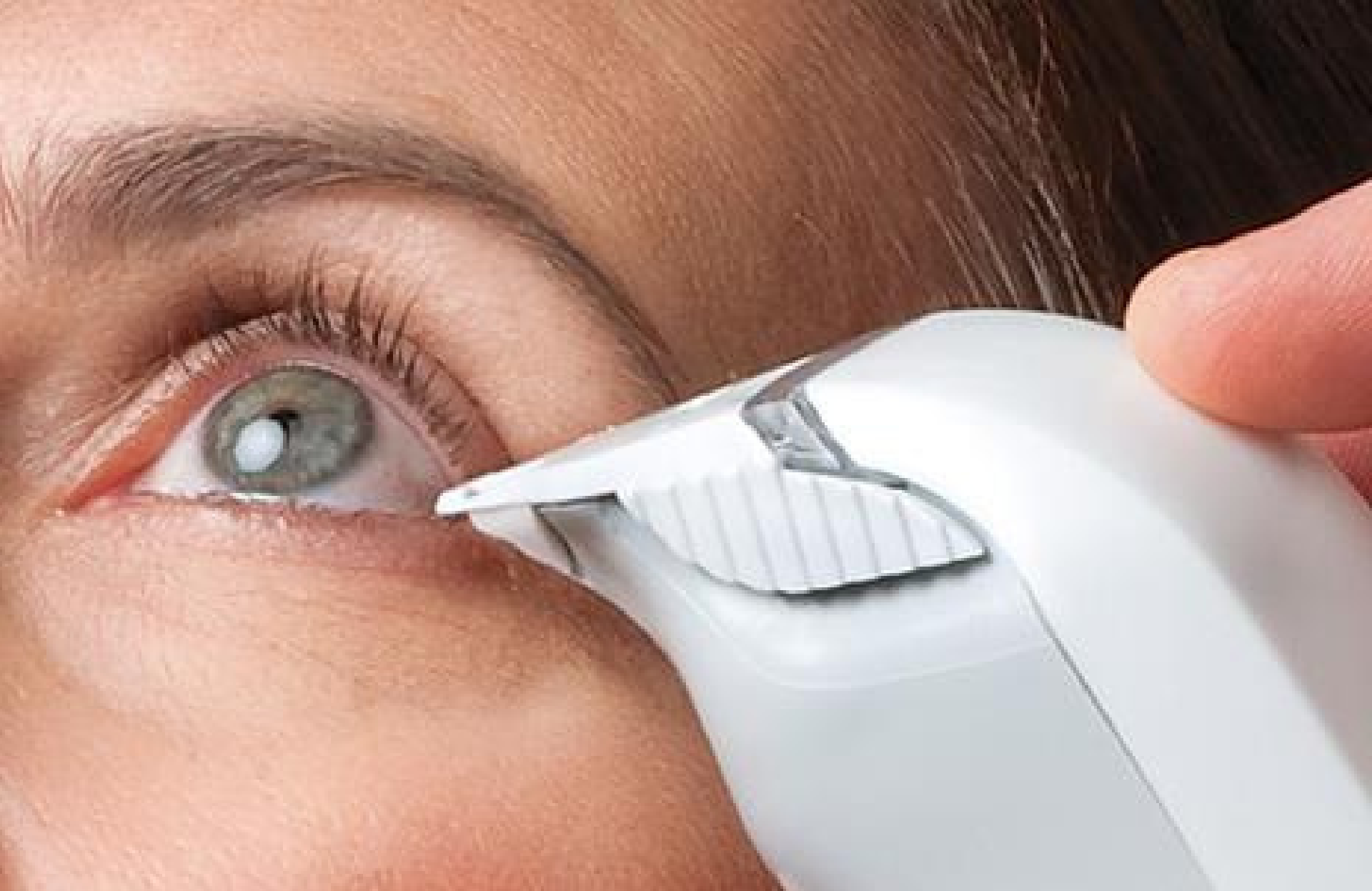- Low volume

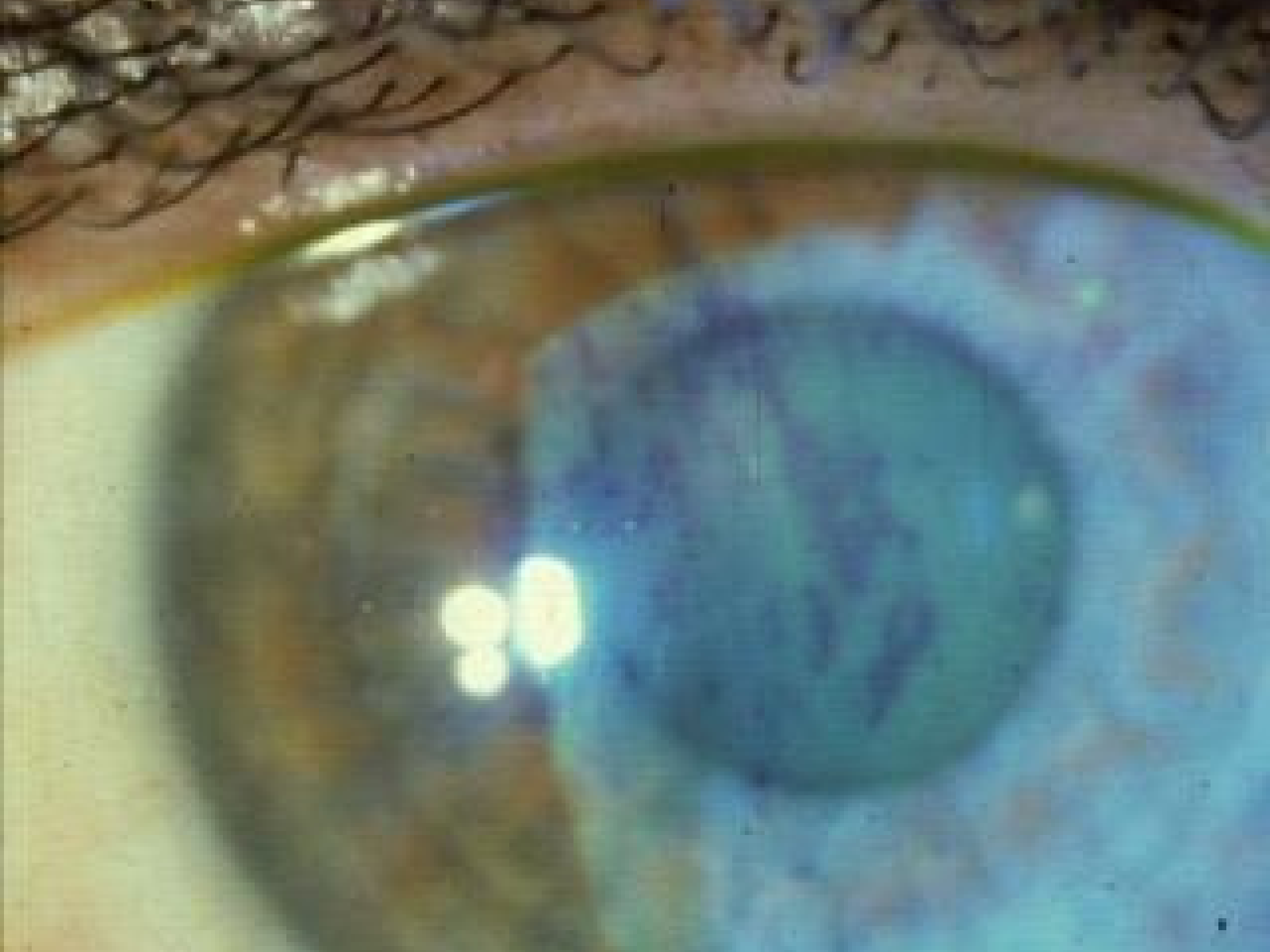

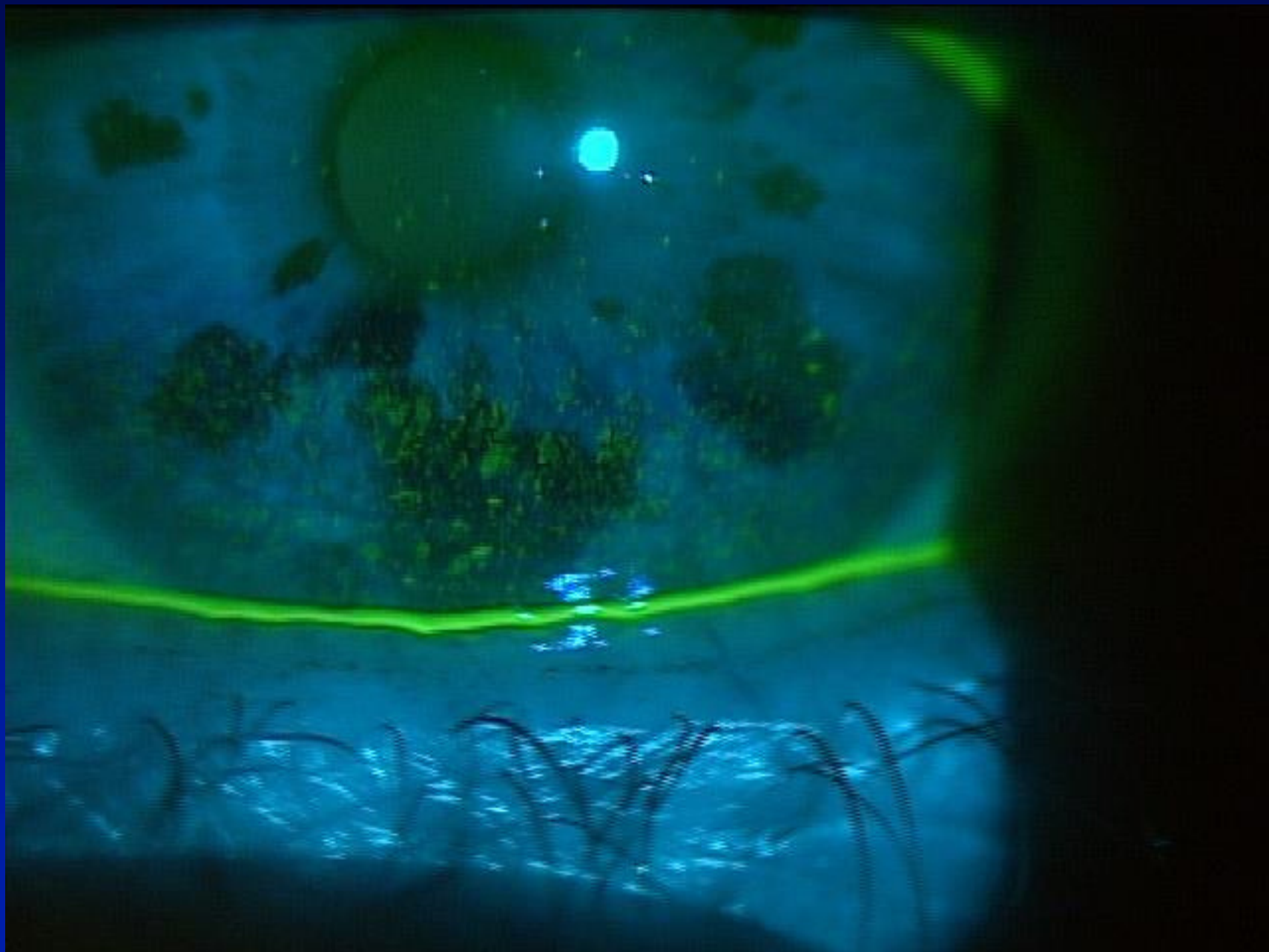
- How severe is the eye discomfort?
 - Do you have any mouth dryness or swollen glands?
 - How long have your symptoms lasted & was there any triggering event?
 - Is your vision affected and does it clear on blinking?
 - Are the symptoms or any redness much worse in one eye than the other?
 - Do the eyes itch, appear swollen or crusty, or have given off any discharge?
 - Do you wear contact lenses?
 - Have you been diagnosed with any general health conditions (including recent respiratory infections) or are you taking any medications?
- + detailed anterior eye examination differential diagnosis where indicated by answers

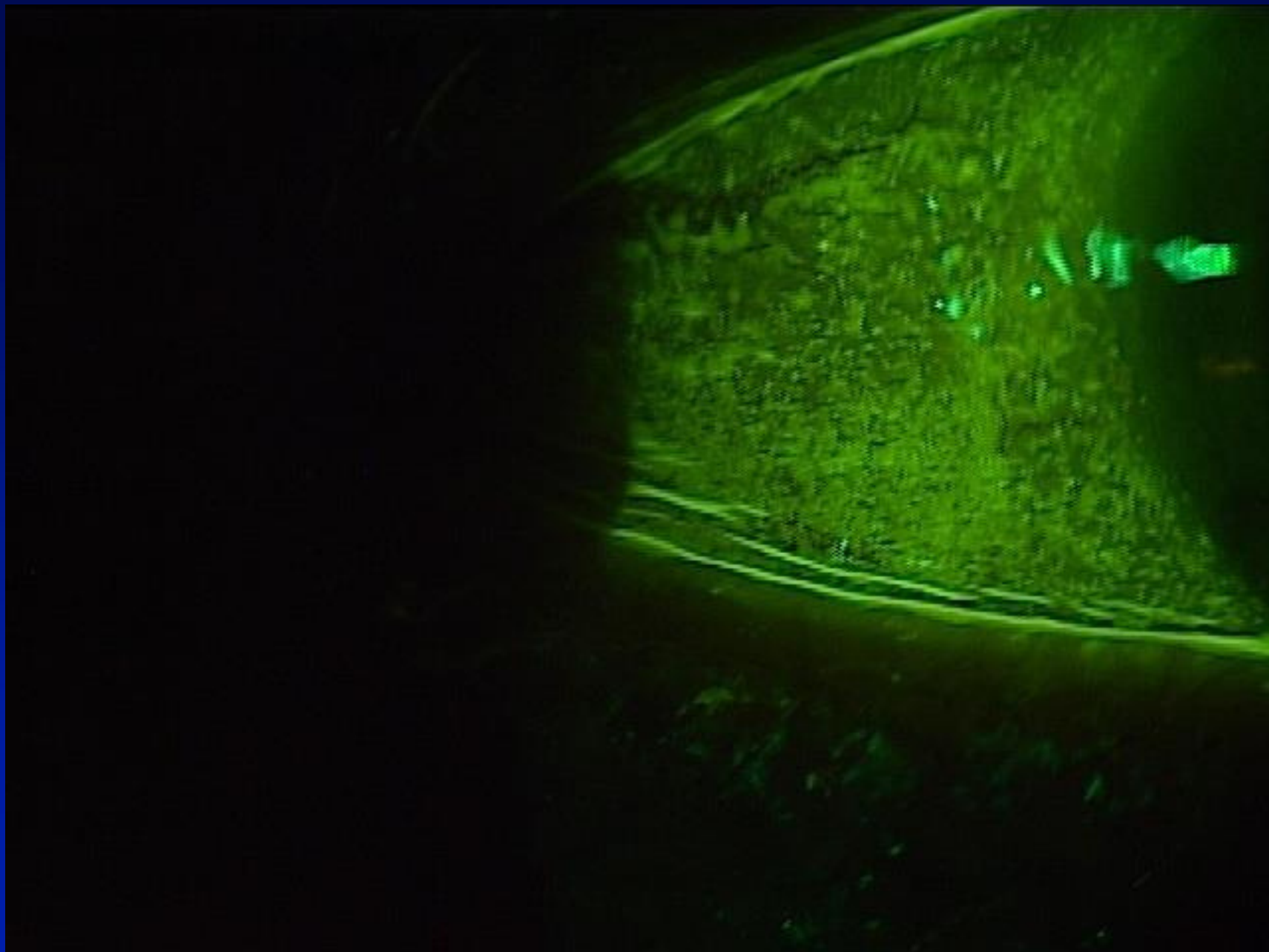
* only to be used if NIBUT not available and if so, after osmolarity











Identify the Sub-type of DED

MGD lid margin drop-out, displacement, secretion ≥ 13 , expressibility 3
 + lipid pattern absent / globular / abnormal colored fringes
 plugging, vascularity, secretion 8-12, expressibility 2
 + lipid pattern meshwork / wave (flow)
 secretion 4-7, expressibility 1
 + lipid pattern amorphous / color fringes

e.g. smoking, certain medications,
 contact lens wear

▶ **START**

Triaging Questions

Risk Factor Analysis

Suspect dry eye

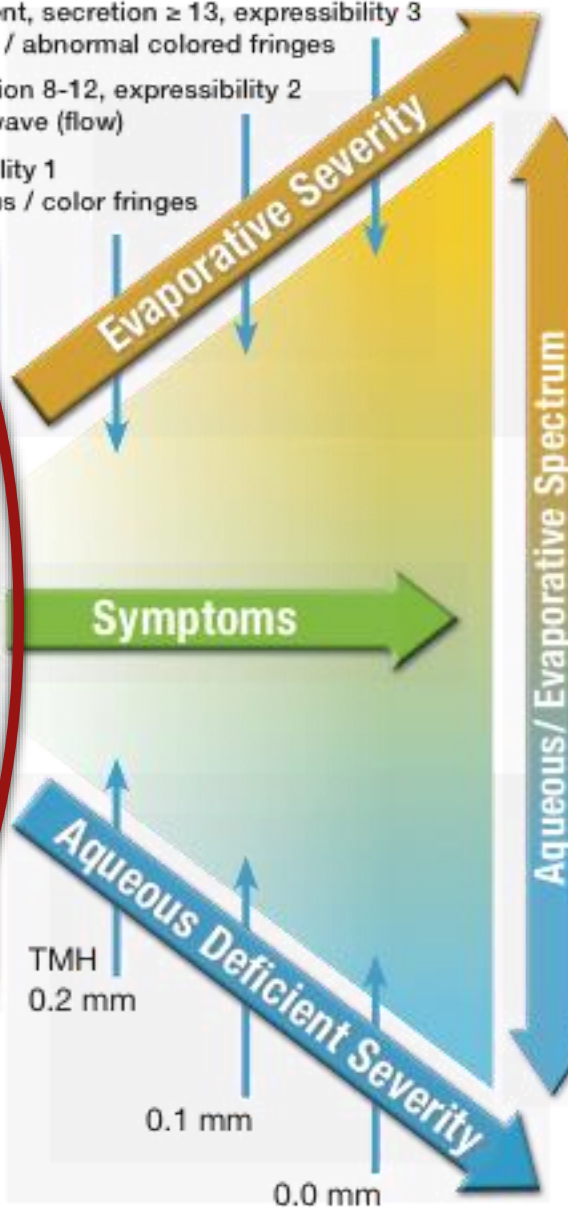
Diagnostic Tests

Screening	Homeostasis Markers
Symptomatology (DEQ-5 ≥ 6 or OSDI ≥ 13)	Non-invasive [fluorescein]* Tear Breakup Time < 10s
	Osmolarity ≥ 308 mOsm/L in either eye or interocular difference > 8 mOsm/L
	Ocular Surface Staining > 5 corneal spots, > 9 conjunctival spots, or lid margin [≥ 2 mm length & $\geq 25\%$ width]

+ 1 of

Subtype Classification Tests

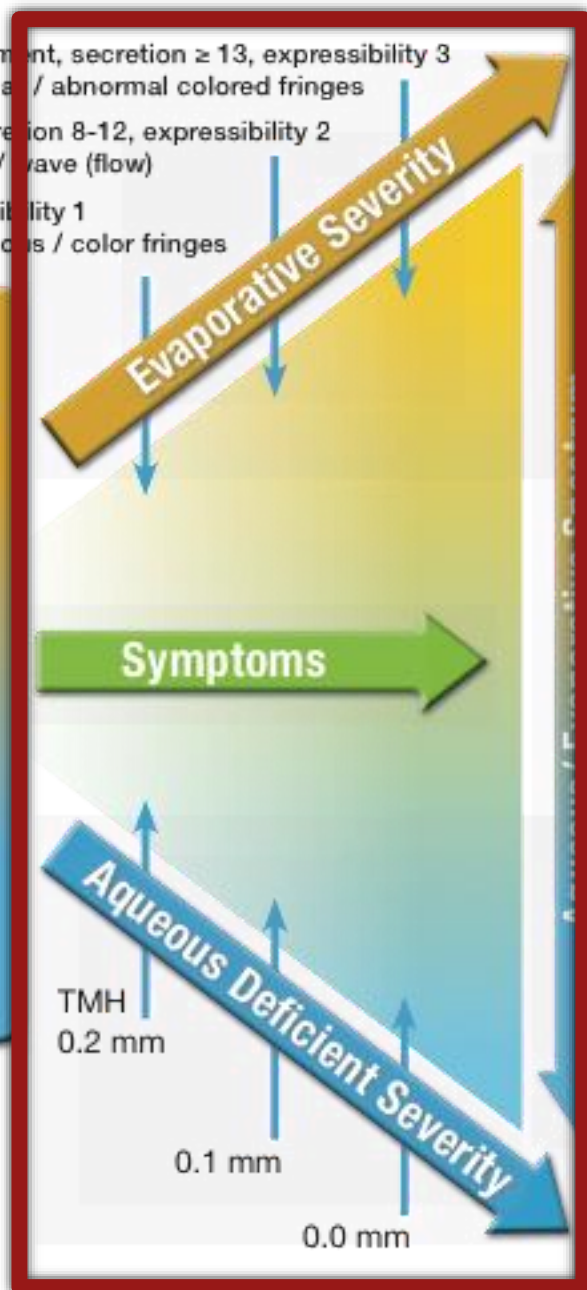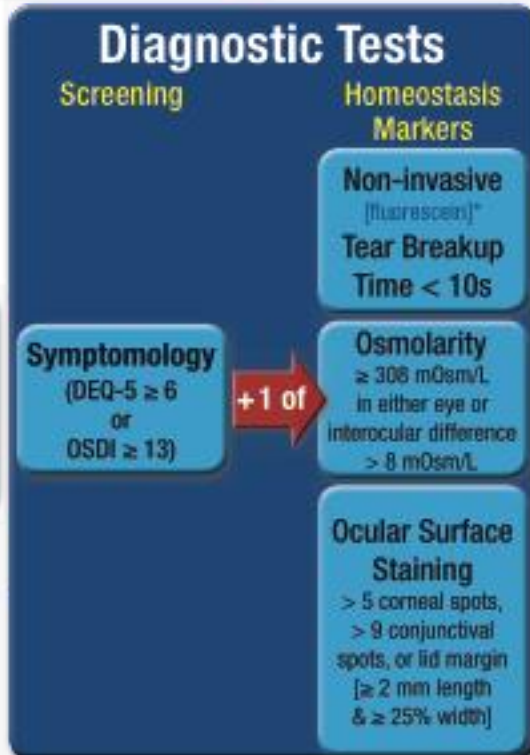
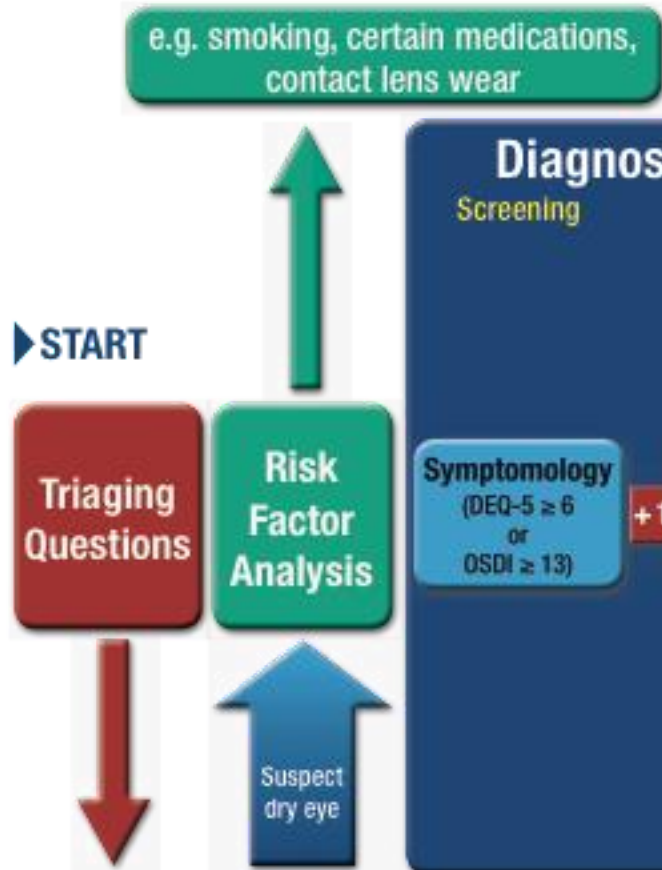
- Evaporative
 - Abnormal lipid
 - MGD
- Aqueous Deficiency
 - Low volume



- How severe is the eye discomfort?
 - Do you have any mouth dryness or swollen glands?
 - How long have your symptoms lasted & was there any triggering event?
 - Is your vision affected and does it clear on blinking?
 - Are the symptoms or any redness much worse in one eye than the other?
 - Do the eyes itch, appear swollen or crusty, or have given off any discharge?
 - Do you wear contact lenses?
 - Have you been diagnosed with any general health conditions (including recent respiratory infections) or are you taking any medications?
- + detailed anterior eye examination differential diagnosis where indicated by answers

* only to be used if NIBUT not available and if so, after osmolarity





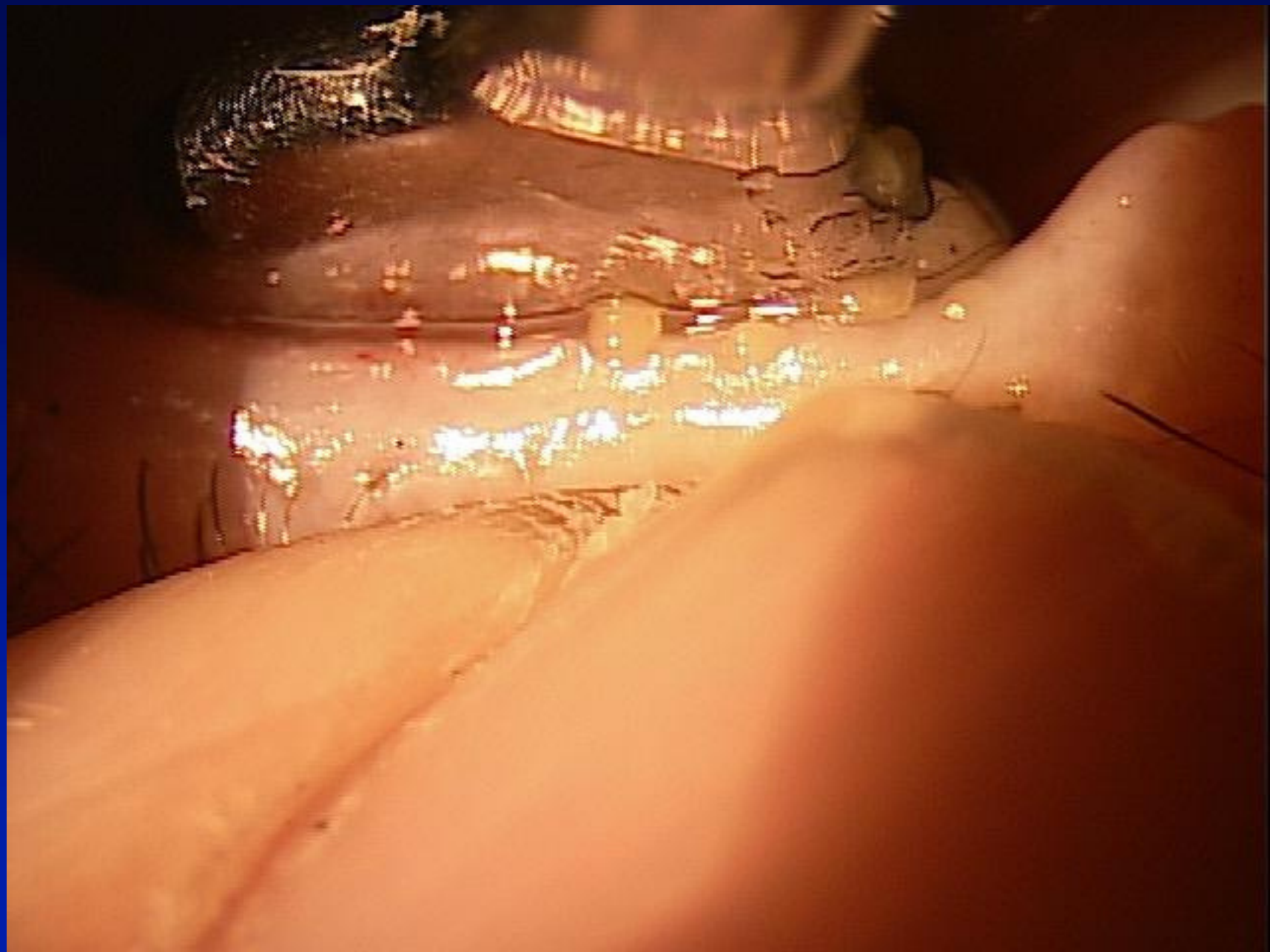
MGD lid margin drop-out, displacement, secretion ≥ 13 , expressibility 3 + lipid pattern absent / globular / abnormal colored fringes

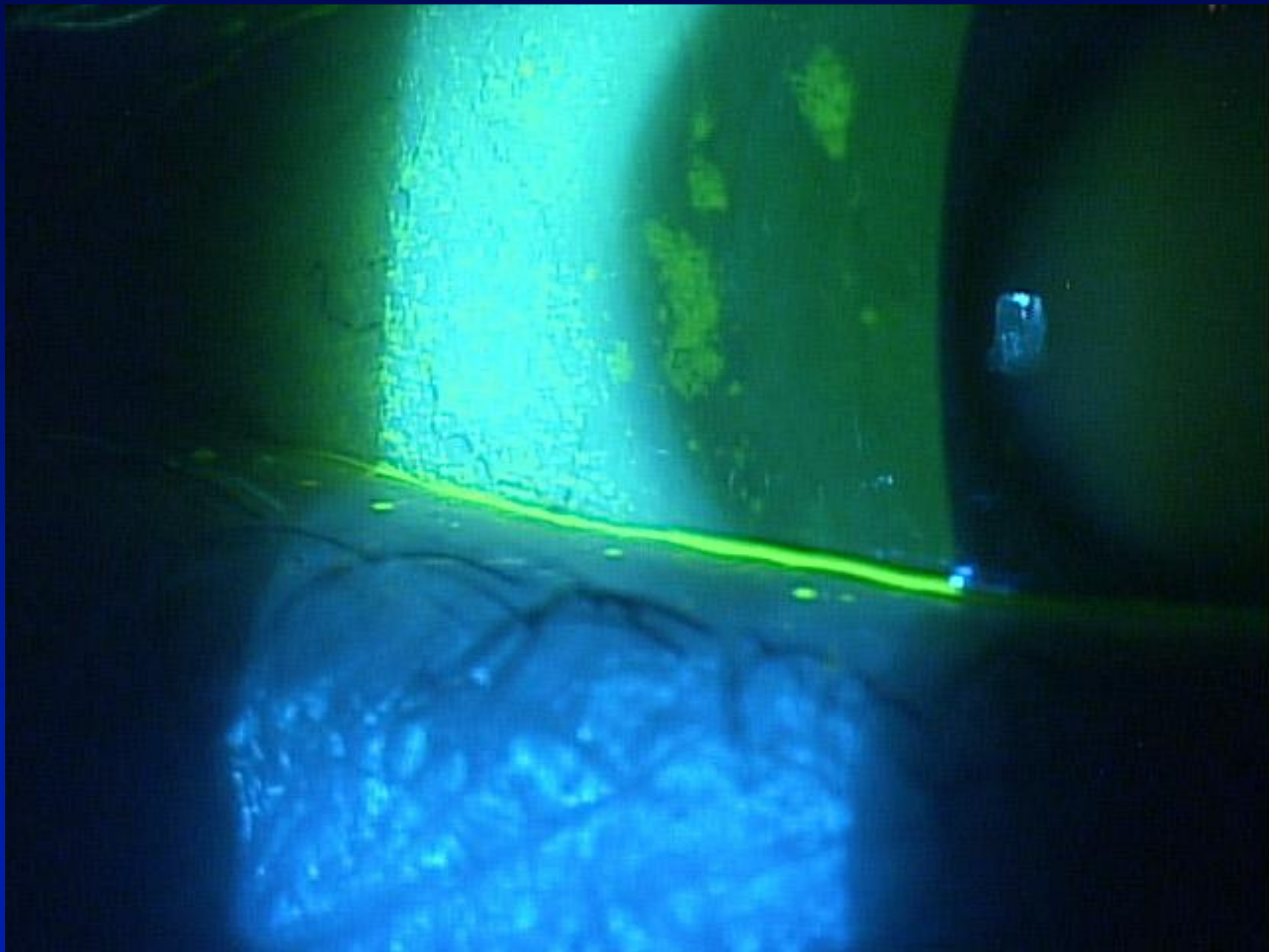
plugging, vascularity, secretion 8-12, expressibility 2 + lipid pattern meshwork / wave (flow)

secretion 4-7, expressibility 1 + lipid pattern amorphous / color fringes

- How severe is the eye discomfort?
 - Do you have any mouth dryness or swollen glands?
 - How long have your symptoms lasted & was there any triggering event?
 - Is your vision affected and does it clear on blinking?
 - Are the symptoms or any redness much worse in one eye than the other?
 - Do the eyes itch, appear swollen or crusty, or have given off any discharge?
 - Do you wear contact lenses?
 - Have you been diagnosed with any general health conditions (including recent respiratory infections) or are you taking any medications?
- + detailed anterior eye examination differential diagnosis where indicated by answers

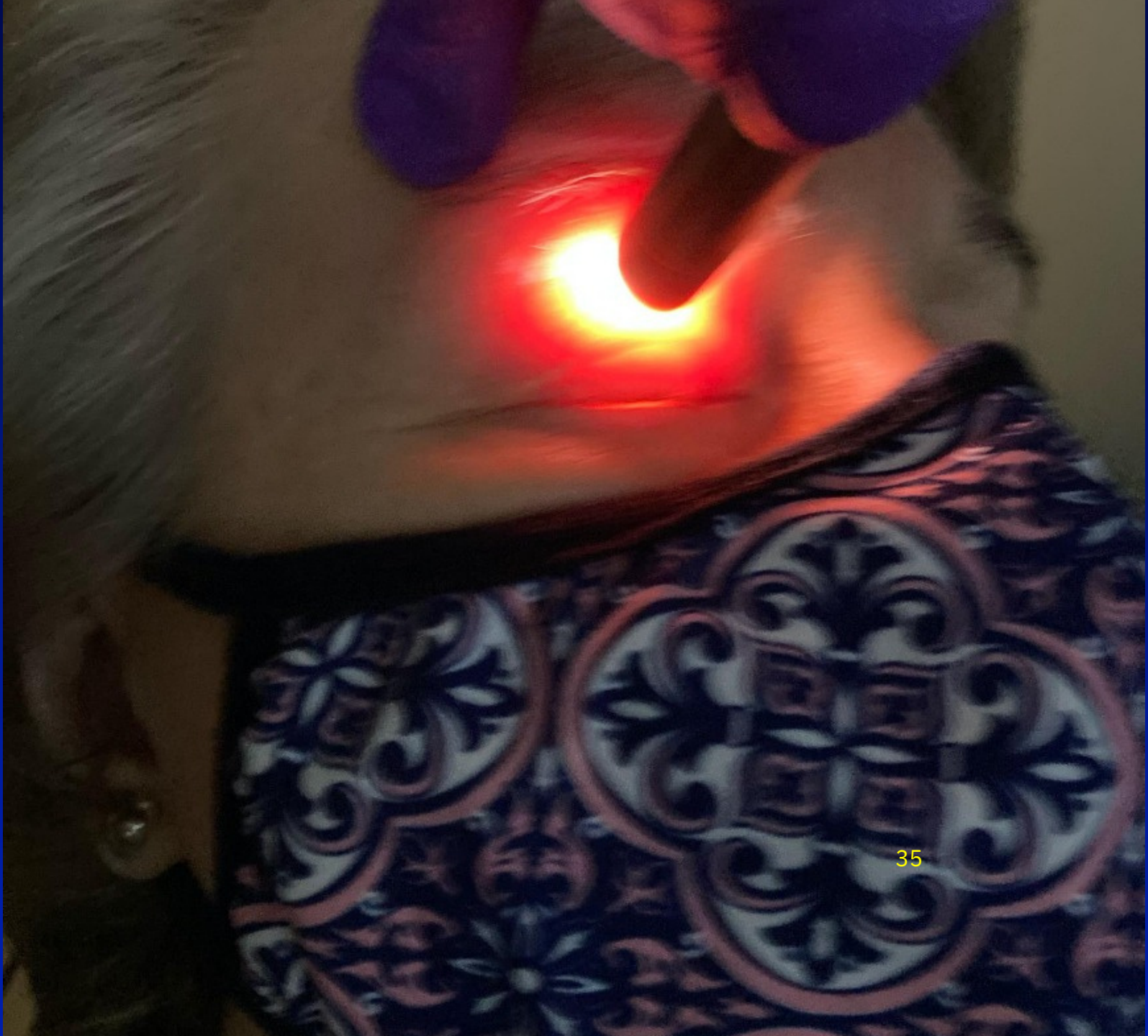* only to be used if NIBUT not available and if so, after osmolarity





Diagnostic Summary

1. Symptoms (most significant and when)
2. Global test for homeostasis
 - Ocular surface staining or
 - TFBUT or
 - Osmolarity
3. Subtype
 - MG Expression
 - Meniscus height



Thank You

karpecki@karpecki.com

www.ophtalmicresources.com